

Eagle syndrome: a comprehensive review of an underestimated condition

Síndrome de Eagle: una revisión comprensiva de una condición subestimada

Marco Xavier Vizúete Bolaños¹ Mario Alberto Teliz Meneses² Oskar Eduardo Prada Vidarte¹ James Philippe Jerez Robalino¹ Oscar Rohel Hernández Ortega¹ Edgar Patricio Olmedo Bastidas¹ Reyna Abigail Miranda Gallegos¹

¹ Resident of Oral and Maxillofacial Surgeon, National Autonomous University of Mexico - UNAM ORCID: 0000-0001-6139-6836

² Oral and Maxillofacial Surgeon, Universidad Nacional Autónoma de México-UNAM. ORCID: 0000-0002-7839-6987.

Correspondence

Marco Vizúete Bolaños
Oral and Maxillofacial Surgeon
National Autonomous University of Mexico - UNAM
Mexico City
Mexico

E-mail: marcovizúete5@gmail.com

ORCID:

Marco Xavier Vizúete Bolaños	0000-0001-6139-6836
Mario Alberto Teliz Meneses	0000-0002-7839-6987
Oskar Eduardo Prada Vidarte	0000-0002-8827-6209
James Philippe Jerez Robalino	0000-0002-3441-424X
Oscar Rohel Hernández Ortega	0000-0003-3872-8438
Edgar Patricio Olmedo Bastidas	0000-0001-9991-4010
Reyna Abigail Miranda Gallegos	0000-0001-8022-5717

VIZUETE BMX, TELIZ MMA, PRADA VOE, JEREZ RJP, HERNÁNDEZ OOR, OLMEDO BEP, MIRANDA GRA. Eagle syndrome: a comprehensive review of an underestimated condition. *Craniofac Res.* 2023; 2(1):15-21.

RESUMEN: The eagle syndrome (ES) is a commonly misdiagnosed condition caused primarily by it has a variety of signs and symptoms. Recent studies relate (ES) to some types of craniofacial pain that can be confused with other diseases and cause cerebrovascular accidents due to carotid artery dissection if this condition is considered a dynamic/positional pathology. It's important to have a multidisciplinary approach to the (ES) that allow us to understand it's pathophysiology, main clinical patterns, diagnostic methods, and treatments. The aim of this manuscript is to carry out an exhaustive review of the pathophysiology, clinical patterns, available diagnostic tools, treatments, and the presentation of a clinical case to guide clinicians through this underestimated condition.

KEY WORDS: Styloid process, neck pain, calcification, neck angulation.

INTRODUCCIÓN

The eagle syndrome (ES) is a rare and still poorly understood clinical condition; that encompasses several symptoms, with pain in the lateral region of the neck being the most predominant symptom and caused by a pathological elongation or angulation of the styloid process (SP) that generates a neurological and vascular occlusion (Arbildo *et al.*, 2016).

Both the SP, stylohyoid ligament (SL) and the lesser horn of the hyoid bone develop from endochondral ossification of the second brachial or Reichert cartilage (Badhey *et al.* 2017). At 3 months, this Reichert cartilage breaks down and divides into five components: the

tympanohyal, the stylohyal, the ceratohyal, the hypohyal, and the basihyal; both the tympanohyal and stylohyal components will make up the (SP) (Fusco *et al.*, 2012).

The name of the styloid process comes from the Greek word "stylos" which means "pillar", this prominence emerges from the surface of the base of the skull, it belongs to the temporal bone specifically at the junction of the petrous and tympanic portions, it is also found anterior and medial to the mastoid process, it lies lateral to the jugular foramen, posterior and lateral to the carotid canal foramen, and immediately anterior and slightly medial to the stylomastoid foramen (Badhey *et al.* 2017; Fusco *et al.*, 2012).

The stylopharyngeus, stylohyoid, and styloglossus muscles originate from the SP, as do the stylohyoid and stylomandibular ligaments. Medial to the SP are the internal carotid arteries, internal maxillary arteries, internal jugular vein, the nerves: glossopharyngeal, pneumogastric, trigeminal and facial nerve branches; while the hypoglossal nerve, cervical sympathetic chain and branches of the ansa cervicalis run in a posteriorly, laterally and inferiorly direction. The relationship that (SP) maintains with these anatomical structures is highly relevant in the pathophysiology of Eagle syndrome (Fusco *et al.*, 2012; Vieira *et al.*, 2015).

In 1652, the Italian surgeon Pietro Marchetti was the first to describe symptoms associated with elongated (SP) with (EL) ossification in patients with intermittent respiratory distress. Weinlecher first described preoperative and postoperative symptoms related to an elongated (EP) in 1872 [5]. However, the definitive syndrome would be established by Watt Eagle (1937 and 1949), who initially used the term "stylalgia" and later, when describing common characteristics of the disease in 200 patients with (SP) elongation, (EL) calcification, or both, was then named as the "Eagle syndrome" (Arbildo *et al.*, 2016; Fusco *et al.*, 2012).

Recent studies estimate that between 30-36% of the world population present at least one elongated (SP), of which only 4-10.3% present painful symptoms, but it's likely that the incidence of the (ES) is underestimated, since there are documented cases in patients with normal (SP) and extrinsic compression of anatomical structures (Piagkou *et al.*, 2009). The highest prevalence of the disease is found in women (69%) with an age range between 41-46 years and Caucasian people in 91%. When comparing both (SPs), studies suggest that the right-sided (SP) has a greater elongation than the left-sided (SP) (Waters *et al.*, 2019). However, a reliable exact value cannot be given due to the wide variation found in the literature due to diagnostic criteria, imaging interpretation, geographic location, and characteristics of the local population (Santini *et al.*, 2012).

The main cause of (SP) ossification is not yet clear, but there are factors associated with (ES) symptoms such as: history of accidents or cervical trauma, history of tonsillectomy, hereditary and endocrine changes such as menopause and pregnancy (Spalthoff *et al.*, 2016).

In the same way, there are different theories that try to explain its cause, such as the 3 theories proposed by Steinmann (Galletta *et al.*, 2019a) (Table I).

Eagle suggested that the normal length of the (SP) is 25mm and that any length greater than this would be considered an elongation (Al Weteid *et al.*, 2015). However, with the advancement of radiographs and computed tomography, it has been possible to describe an average (SP) length between 21-29.5mm; therefore, it is considered that a (SP) length greater than 30mm confers a greater probability of having (ES) (Saccomanno *et al.*, 2021).

Clinical patterns of Eagle syndrome:

- Neuropathic Eagle Syndrome (NES): also known as "classic ES" in which the majority of patients report a previous tonsillectomy surgery or a recent cervical trauma, developing a loco-regional compressive neuropathy of cranial nerves VII, IX, X and XII. The areas of discomfort are located in the neck and at the back of the throat, it's main symptoms are pain at the base of the tongue and in the tonsils,odynophagia, otalgia, tinnitus and sensation of having a foreign object in the throat (Piagkou *et al.*, 2009).

Analysis of this type of conditions include: 1) intraoral palpation of the tip of the elongated (SP) in the tonsillar region and 2) decrease in pain after intraoral infiltration of local anesthetic (2% lidocaine) in the lower part of the tonsillar region (Saccomanno *et al.*, 2021).

- Carotid Eagle Syndrome (CES): also known as "vascular ES" is that in which the elongated (SP) is very close to the internal carotid artery causing vascular compression and

Table I. Elongation and calcification of the styloid process theories.

Theories	Description
Reactive hyperplasia	Surgery or chronic trauma to the throat that may cause tendinitis, periostitis ossificans, or osteitis of the stylohyoid ligament.
Reactive metaplasia	Partial ossification of the fibrocartilaginous tissue of the stylohyoid ligament secondary to previous trauma.
Anatomical variation	(SP) elongation and ossification of the stylohyoid ligament as a variant without a history of previous trauma.
Congenital elongation	Persistence of the mesenchymal lamina that reacts to mechanical stress during fetal development and produces bone tissue in the stylohyoid ligament.

generating different symptoms such as periorbital and parietal pain, dizziness, syncope or even more serious conditions such as transient ischemic attacks, thromboembolism or cerebrovascular accident due to dissection of the internal carotid artery. Studies indicate that this condition due to vascular compression is related to flexo-extension, inclination and rotation type movements of the head and neck (Spalthoff. *et al.*, 2016; Galletta *et al.*, 2019a; Saccomanno *et al.*, 2021).

- Jugular Eagle Syndrome (JES): recent studies have described a new pathological entity called Styloidogenic Jugular Venous Compression Syndrome (SJVCS) which consists of compression of the internal jugular vein during dynamic movements of the head and neck, causing an increased intracranial venous pressure. This new entity gave rise to new origin theories of clinical conditions of unknown etiology such as migraine, Meniere's syndrome or pulmonary embolism of unknown etiology (Galletta *et al.*, 2019a; Saccomanno *et al.*, 2021).
- Compas Eagle Syndrome (CoES): is a condition that can present in both (CES) or (JES) where there is a juxtaposition of the transverse process of the C1 cervical vertebra, vascular bundle and (SP) during head movements, producing symptoms such as neck pain and otalgia even if (SP) length is normal (Arbildo *et al.*, 2016; Saccomanno *et al.*, 2021).

Diagnosis

Orthopantomography (OPG)

The different clinical patterns rarely allow us to have a correct diagnosis, therefore, the use of imaging tools such as OPG are of great help due to their ease of attainment, low cost and low radiation dose (Arbildo *et al.*, 2016).

Langlais *et al.* in 1986 made a classification according to the patterns of elongation and calcification of (SP) (Fig. 1). Three radiographic patterns can be found (Costantinides *et al.*, 2013).

- Type I (elongated): an uninterrupted and radiographically elongated (SP) (>30mm).
- Type II (Pseudo-articulate): a (SP) with two mineralized segments joined by a pseudo-articulation.
- Type III (segmented): a (SP) with two or more non-continuous mineralized segments.

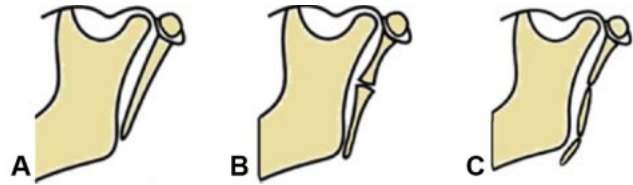


Fig.1: Patterns of elongation and calcification of the styloid process: A) Type I (elongated); B) Type II (pseudo-articulated) and C) Type III (segmented)

The O'Carroll classification, modified by More C. *et al* in 2010, describes 4 varieties according to the length of the (SP) compared to adjacent bone structures (Saccomanno *et al.*, 2021; Al-Amad *et al.*, 2021).

- Type O: the (SP) is not visible in the orthopantomography.
 - Type A: the (SP) apex is above the mandibular foramen.
 - Type B: the (SP) apex is between the mandibular foramen and the angle of the mandible.
 - Type C: the (SP) apex is below the angle of the mandible.
- Both classifications are useful during the first diagnosis, but since they are 2-dimensional images, they present limitations when knowing both the shape and angulation of the (SP), in the same way, as its proximity to soft structures of the neck, since there are cases of symptoms of (ES) where the problem was not the elongation of the (SP), rather it was its inclination (Nastro *et al.*, 2022).

Computed Tomography (CT)

CT is the best imaging modality because it allows us to have more precise (SP) data such as its length, angulation, and mineralization pattern. In the same way, the use of a CT angiography allows us to know the anatomical relationships that the (SP) maintains with surrounding structures of the neck such as blood vessels in cases of (CES) (Langlais *et al.*, 1986).

Doppler ultrasound (DU)

Ikenouchi *et al* mentions the importance of using ultrasound in the cervical and oral region for the detection of (SE) and its proximity to the carotid plaque; They also explain the facilities that (DU) has and the cervical dynamic movement that the patient can adopt to observe some decrease in the diameter of a cervical blood vessel due to compression when related to the (SP). Therefore, the procedure is encouraging

and opens the door to future research for a correct standardization (More and Asrani, 2010; Ikenouchi *et al.*, 2020).

Treatment

The treatment can be conservative or surgical depending on the patient's symptoms. The first treatment is based on the use of first-line analgesics such as nonsteroidal anti-inflammatory drugs (NSAIDs), which can even be combined with anticonvulsant drugs, antidepressants, and even local injections of steroids (Hooker *et al.*, 2016). Han *et al.* suggest the use of pharmacological combinations of Gabapentin, tianeptine, tramadol and paracetamol together with local applications in areas of cervical pain with 1mg of triamcinolone/mepivacaine, reporting an almost complete resolution of symptoms (Han *et al.*, 2013).

Other studies such as that of Taheri *et al.* (2014) who reported an 80% decrease in symptoms when combining 75mg per day of Pregabalin with 10mg per day of amitriptyline. Physiotherapy is another conservative method for managing SE; however, there are reports of transpharyngeal fracture during physical manipulation as well as the possibility of damage to nearby vascular structures (Müderris *et al.*, 2014).

Surgical or definitive treatment can be performed initially or if conservative treatment has failed. Surgery aims at total or partial resection of (SP) mainly through two surgical approaches (intraoral and extraoral-transcervical) (Green *et al.*, 2014). Both approaches have advantages and disadvantages, the intraoral approach mainly presents better aesthetic results and with the extraoral approach a better view of the operative field and management of anatomical structures close to the (SP) are achieved (Nastro *et al.*, 2022). Currently in equipped hospital centers, minimally invasive surgeries such as transoral endoscopy, robotic surgery and navigation-assisted transcervical styloidectomy can be performed. However, each procedure depends on the type of (ES) and the skill of each surgeon (Al Weteid *et al.*, 2015).

The traditional intraoral approach begins with a modified tonsillectomy-like approach that begins with an incision in the anterior tonsillar pillar, followed by digital palpation of the tonsillar region to identify the tip of the (SP), and then blunt dissection at the tonsillar region through the medial

pterygoid and superior constrictor muscles to locate the (SP) (Zamboni *et al.*, 2019). After locating the (SP), its ligamentous and muscular attachments are removed, and finally, as much of the (SP) as possible is fractured (Czako *et al.*, 2020). The main risks of this approach include infection and poor control and vision during bleeding, especially in the case of a carotid injury due to its proximity (Galletta *et al.*, 2019b). Torres *et al.* (Torres *et al.*, 2014) recently reported success with this approach; in addition, transoral approaches have advanced even further, as demonstrated by Al Weteid's endoscopy-assisted approach (Al Weteid *et al.*, 2015).

An external cervical approach provides the best exposure with the downside of a scar. It begins with an oblique incision made at the angle of the mandible and blunt dissection to the sternocleidomastoid muscle, which is retracted posterolaterally (Nastro *et al.*, 2022). The dissection is completed between the parotid gland and the posterior belly of the digastric muscle until the (SP) is found, in which digital palpation can be helpful. Finally, the (SP) fracture is performed with as much bone tissue as possible (Elmas and Shrestha, 2017).

Case illustration

A 56-year-old woman presented to the hospital with a 3-year history of bilateral sore throat andodynophagia. The patient denied dysphagia, weight loss, or other associated symptoms. The patient was treated with analgesics and physiotherapy without sufficient relief. The patient referred a tonsil surgery when she was 8 years old. During intraoral and extraoral palpation of both the peritonsillar and cervical regions caused pain that stopped when she pressure was removed. A computed tomography of the neck with 3D reconstruction was obtained, where both (SPs) were observed to be elongated (Fig. 2). Based on the clinical and radiographic analysis, the diagnosis of "Eagle Syndrome" was given. As the previous conservative treatment did not give a favorable result, surgical intervention was offered and the patient was interested in pursuing this option. The patient underwent a bilateral cervical approach with resection of both styloid processes (Fig. 3). The patient had an immediate resolution of symptoms after waking up in the recovery unit. After a year of evolution, the patient has good healing of both cervical surgical wounds (Fig. 4) and she does not present any symptoms related to SE.

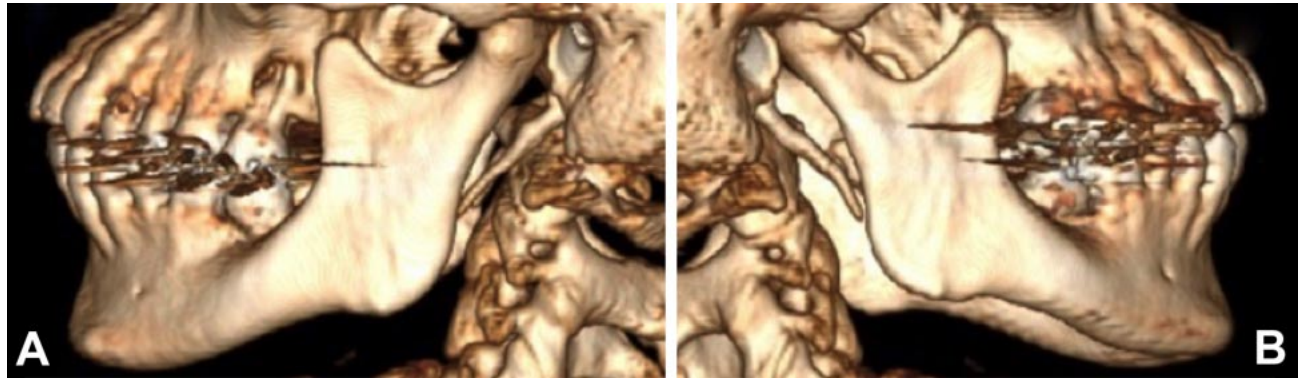


Fig. 2. 3D reconstruction of CT with styloid process elongated: A) left; B) right.

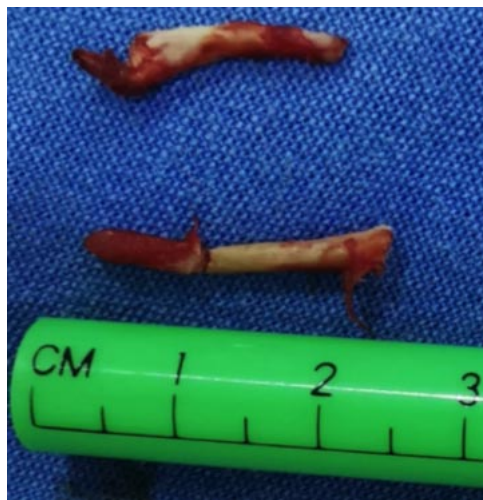

Fig. 3. Elimination of right and left styloid processes.

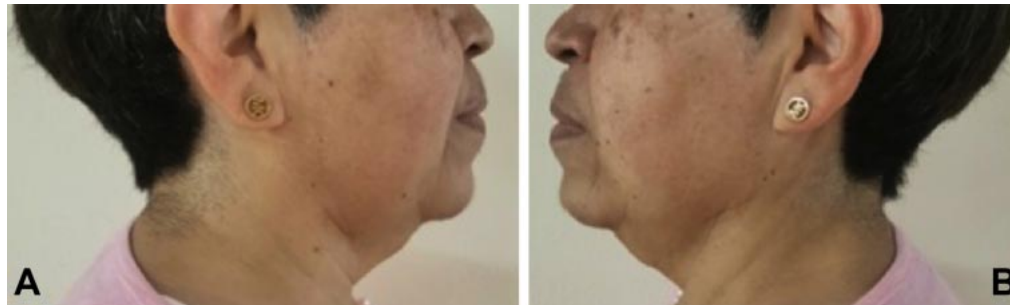

Fig. 4. Extraoral photograph of 1 year of evolution with adequate healing A) right side; B) left side.

DISCUSSION

The (ES) remains a poorly understood and underestimated syndrome due to its variety of signs and symptoms. The neuropathic and vascular patterns of (ES) must be diagnosed indistinctly from each other in their clinical and radiological aspects (Nastro *et al.*, 2021). Recent works have emphasized the importance of a multidisciplinary approach that would

allow physicians to better understand the pathophysiology and the main clinical patterns of such a complicated condition in order to avoid associations with other conditions with similar symptoms (Al Weteid *et al.*, 2015).

The symptoms of (ES) and the position of the head, from turning the head to tilting and flexing, are related, so it is suggested to perform positional images of the neck region and relate the (SP) to cervical anatomical structures (Torres *et al.*, 2014). To better investigate such a relationship, our vision should be focused on the development of new diagnostic approaches such as transoral carotid ultrasound (TCU), magnetic resonance angiography (MRA) and Doppler ultrasound, performed in a "dynamic-positional" manner. According to the most recent literature, the difficulty of diagnosing (ES) is related to the lack of an adequate positioning method (Galletta *et al.*, 2019a). Similarly, recent studies confirm the importance of

the use of new imaging tools in different head movements, (ES) being a "dynamic/positional pathology" (Nastro *et al.*, 2022).

In the studies by Nastro, Siniscalchi and Raffa ratify the importance of performing a dynamic-positional tool as a standard imaging technique in patients who had a

cerebrovascular accident of unknown origin (Siniscalchi, 2020).

Although ES has been described for almost a century, many aspects such as its origin, diagnosis and treatment are still controversial, which is why it's interest has grown in terms of seeking answers and in turn generating new questions such as:

- What pathogenic mechanism separates neuropathic from vascular eagle syndrome?
- What new role does the new term “dynamic/positional pathology” play in the diagnosis of eagle syndrome?
- How many diagnoses of neuropathic or vascular eagle syndrome could have been overlooked or even confused with other pathologies?

Therefore, more studies are needed with the new tools provided from the recent literature to be able to answer the new questions or concerns mentioned above with the aim of improving the diagnosis and management of patients affected by this condition than with the passage of time it becomes less and less difficult to understand. Only an interdisciplinary and up-to-date medical management will allow us to answer all our questions about this rare condition in the future.

Conflict of interests

The authors inform that they have no conflict of interest.

Statement of ethics/confirmation of patient permission

Not applicable for the present study. The patient provided written informed consent for this article to be published following the Declaration of Helsinki.

ACKNOWLEDGEMENTS

* This article is dedicated to each of our families, since without their support none of this would be possible.

This research did not receive any specific grants from funding agencies in the public, commercial, or non-profit sectors.

VIZUETE BMX, TELIZ MMA, PRADA VOE, JEREZ RJP, HERNÁNDEZ OOR, OLMEDO BEP, MIRANDA GRA. Síndrome de Eagle: una revisión comprensiva de una condición subestimada. *Craniofac Res.* 2023; 2(1):15-21.

RESUMEN: El síndrome de Eagle (SE) es una condición usualmente mal diagnosticado causado principalmente por su variedad de signos y síntomas. Estudios recientes relacionan al SE con algunos tipos de dolor craneofacial que llegan ser confundidos con otras enfermedades y también como causante de accidentes cerebrovasculares por disección de la arteria carótida, si se tiene en consideración a esta condición como una patología dinámica/posicional. Es de gran importancia tener un enfoque multidisciplinario del SE que permita

comprender su fisiopatología, los patrones clínicos principales, métodos de diagnóstico y sus tratamientos. El objetivo de este trabajo es el de realizar una revisión de la fisiopatología, patrones clínicos, herramientas diagnósticas disponibles, tratamientos y la presentación de un caso clínico de ejemplo con el fin de guiar a los clínicos a través de esta condición aun subestimada.

PALABRAS CLAVE: Proceso estiloides, dolor cervical, calcificación y angulación cervical.

REFERENCES

- Al Weteid AS, Miloro M. Transoral endoscopic-assisted styloidectomy: How should Eagle syndrome be managed surgically? *Int J Oral Maxillofac Surg.* 2015;44:1181-7. doi: 10.1016/j.ijom.2015.03.021.
- Al-Amad SH, Al Bayatti S, Alshamsi HA. The effect of styloid process medial angulation on Eagle's syndrome's self-reported symptoms: A preliminary cross-sectional study. *Oral Surg Oral Med Oral Pathol Oral Radiol.* 2021;132:52-56. doi: 10.1016/j.oooo.2021.02.013.
- Arbildo H, Gamarra L, Rojas S, Infantes E & Vásquez H. Eagle syndrome. A narrative review. *J Oral Res* 2016;5:248-254.
- Badhey A, Jategaonkar A, Anglin Kovacs AJ, Kadakia S, De Deyn PP, Ducic Y, Schantz S, Shin E. Eagle syndrome: A comprehensive review. *Clin Neurol Neurosurg.* 2017;159:34-38. doi: 10.1016/j.clineuro.2017.04.021.
- Costantinides F, Vidoni G, Bodin C, Di Lenarda R. Eagle's syndrome: signs and symptoms. *Cranio.* 2013;31:56-60. doi: 10.1179/crn.2013.008
- Czako L, Simko K, Thurzo A, Galis B, Varga I. The Syndrome of Elongated Styloid Process, the Eagle's Syndrome-From Anatomical, Evolutionary and Embryological Backgrounds to 3D Printing and Personalized Surgery Planning. Report of Five Cases. *Medicina (Kaunas).* 2020;56:458. doi: 10.3390/medicina56090458
- Elmas F., Shrestha B.L. Eagle's Syndrome. *N. Engl. J. Med.* 2017;377:e18. doi: 10.1056/NEJMicm1703542
- Fusco DJ, Asteraki S, Spetzler RF. Eagle's syndrome: embryology, anatomy, and clinical management. *Acta Neurochir.* 2012;154:1119-26. doi: 10.1007/s00701-012-1385-2.
- Galletta K, Siniscalchi EN, Cicciù M, Velo M, Granata F. Eagle syndrome: a wide spectrum of clinical and neuroradiological findings from cervico-facial pain to cerebral ischemia. *The Journal of craniofacial surgery.* Published online 2019. <https://doi.org/10.1097/SCS.00000000000005453>
- Galletta K., Granata F., Longo M., Alafaci C., De Ponte F.S., Squillaci D., De Caro J., Grillo F., Benedetto F., Musolino R., et al. An unusual internal carotid artery compression as a possible cause of Eagle syndrome—A novel hypothesis and an innovative surgical technique. *Surg. Neurol. Int.* 2019;10:174. doi: 10.25259/SNI_317_2019.
- Green BN, Browske LK, Rosenthal CM. Elongated styloid processes and calcified stylohyoid ligaments in a patient with neck pain: implications for manual therapy practice. *J Chiropr Med.* 2014;13:128-33. doi: 10.1016/j.jcm.2014.06.006.
- Han MK, Kim DW, Yang JY. Non Surgical Treatment of Eagle's Syndrome - A Case Report -. *Korean J Pain.* 2013;26:169-72. doi: 10.3344/kjp.2013.26.2.169.
- Hooker JD, Joyner DA, Farley EP, Khan M. Carotid stent fracture from stylocarotid syndrome. *J Radiol Case Rep* 2016;10(6):1-8. <https://doi.org/10.3941/jrcr.v10i6.1618>.

- Ikenouchi H, Takagi M, Nishimura A, *et al.* Bilateral carotid artery dissection due to Eagle syndrome in a patient with vascular Ehlers-Danlos syndrome: a case report. *BMC Neurol.* 2020;20:285. <https://doi.org/10.1186/s12883-020-01866-2>.
- Langlais RP, Miles DA, Van Dis ML. Elongated and mineralized stylohyoid ligament complex: a proposed classification and report of a case of Eagle's syndrome. *Oral Surg - Oral Med Oral Pathol.* 1986;61:527-32. [https://doi.org/10.1016/0030-4220\(86\)90400-7](https://doi.org/10.1016/0030-4220(86)90400-7).
- More CB, Asrani MK. Evaluation of the styloid process on digital panoramic radiographs. *Indian J Radiol Imag.* 2010;20:261. <https://doi.org/10.4103/0971-3026.73537>.
- Müderris T, Bercin S, Sevil E, Beton S, Kırıs M. Surgical management of elongated styloid process: intraoral or transcervical? *Eur Arch Otorhinolaryngol.* 2014;271:1709-13. doi: 10.1007/s00405-013-2664-0.
- Nastro E., Raffa G., Vinci S., Granata F., Pitrone A., Tessitore A., *et al.* Eagle syndrome: Lights and shadows of an underestimated condition of multidisciplinary interest. *Advances in Oral and Maxillofacial Surgery.* 2022;5:100243. <https://doi.org/10.1016/j.adoms.2021.100243>
- Nastro Siniscalchi E, Raffa G, Germanò A, De Ponte FS, Galletti F. Regarding Chronic Cerebrospinal Venous Insufficiency and Meniere's Disease: Interventional Versus Medical Therapy. *Laryngoscope.* 2021;131:E980. doi: 10.1002/lary.28870.
- Piagkou M, Anagnostopoulou S, Kouladouros K, Piagkos G. Eagle's syndrome: a review of the literature. *Clin Anat.* 2009;22:545-58. doi: 10.1002/ca.20804.
- Saccomanno S, Quinzi V, D'Andrea N, Albani A, Coceani Paskay L, Marzo G. Traumatic Events and Eagle Syndrome: Is There Any Correlation? A Systematic Review. *Healthcare (Basel).* 2021;29;9:825. doi: 10.3390/healthcare9070825.
- Santini L, Achache M, Gomert R, Mardassi A, Lafont B, Magnan J, Lavielle JP, Devèze A. Transoral surgical treatment of Eagle's syndrome: case report and review of literature. *Rev Laryngol Otol Rhinol (Bord).* 2012;133:141-4.
- Siniscalchi EN. Dynamic imaging in suspected Eagle syndrome. *Eur Arch Otorhinolaryngol.* 2020;277:307. doi: 10.1007/s00405-019-05678-0.
- Spalthoff S, Zimmerer R, Dittmann O, Tavassol F, Dittmann J, Gellrich NC, Jehn P. Piezoelectric surgery and navigation: a safe approach for complex cases of Eagle syndrome. *Int J Oral Maxillofac Surg.* 2016;pii:S0901-5027:30068-6.
- Taheri A, Firouzi-Marani S, Khoshbin M. Nonsurgical treatment of stylohyoid (Eagle) syndrome: a case report. *J Korean Assoc Oral Maxillofac Surg.* 2014;40:246-9. doi: 10.5125/jkaoms.2014.40.5.246.
- Torres AC, Guerrero JS, Silva HC. A modified transoral approach for carotid artery type Eagle syndrome: technique and outcomes. *Ann Otol Rhinol Laryngol.* 2014;123:831-4. doi: 10.1177/0003489414538770.
- Vieira EM, Guedes OA, Morais SD, Musis CR, Albuquerque PA, Borges ÁH. Prevalence of Elongated Styloid Process in a Central Brazilian Population. *J Clin Diagn Res.* 2015;9:ZC90-2.
- Waters CM, Ho S, Luginbuhl A, Curry JM, Cognetti DM. Surgical Management of Stylohyoid Pain (Eagle's) Syndrome: A 5-Year Experience. *Ann Otol Rhinol Laryngol.* 2019;128:220-226. doi: 10.1177/0003489418816999.
- Zamboni P., Scerrati A., Menegatti E., Galeotti R., Lapparelli M., Traina L., *et al.* The eagle jugular syndrome. *BMC Neurol* 2019;19:333. <https://doi.org/10.1186/s12883-019-1572-3>.